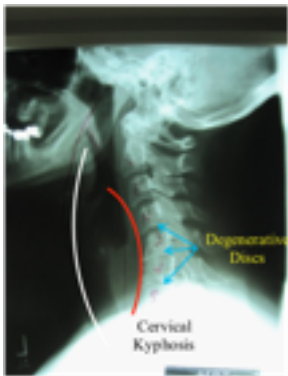

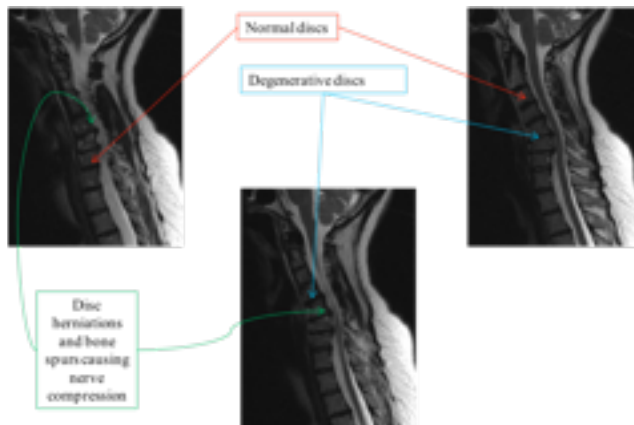
## Cervical Kyphosis Patient File



This radiograph demonstrates loss of the normal curvature of the spine due to degenerative (“worn out”) discs. Due to the degeneration, the vertebrae (bones of the spine) start collapsing on each other resulting in a forward lean of the head and neck. This is associated with neck and shoulder pain as the muscles on the neck have to work harder to hold up the head & prevent it from falling forward. There is also stretching (and pain) of these posterior neck muscles as the alignment worsens.

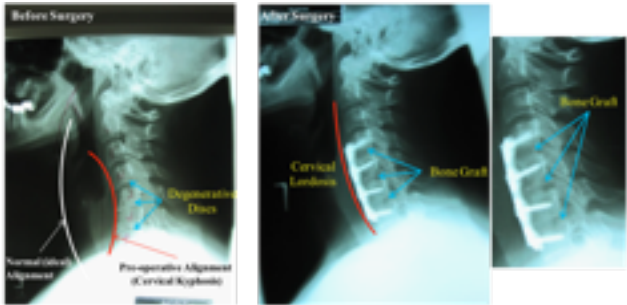
While the white line represents normal spinal alignment (what the spine should look like), the red line demonstrates the current malalignment (the curve of the spine is in the opposite direction of normal) known as “*cervical kyphosis*.”

## Patient File 6 (continued)



MRI of the same patient demonstrates multiple degenerative discs with herniation and bone spurs that cause nerve compression and account for the pain and numbness in her neck and arms.

## Patient File 6 (continued)



The patient's pain did not improve with NON-operative treatment and she underwent a C4-7 anterior cervical discectomy and fusion. The radiograph on the left shows her spinal alignment before the surgery and the one on the right shows her spine after surgery. Note the improvement in alignment and the placement of bone in space vacated by the degenerative discs. Also note that the bone placed where the disc was removed has mended with her own bone and thus "fusion" has occurred. She was in the hospital overnight and went home the following day. The pain in her neck, numbness and tingling in her neck and arms completely resolved.